



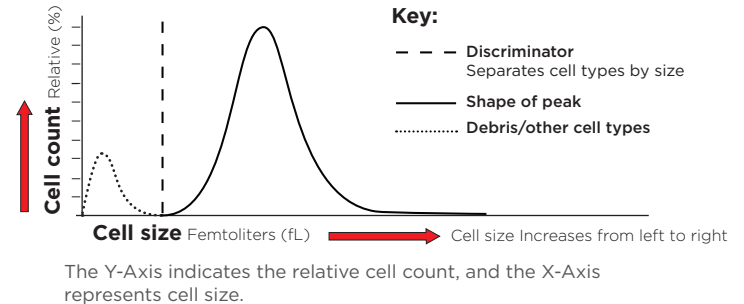
INTERPRETING HISTOGRAMS

HM5

Elements of a Histogram

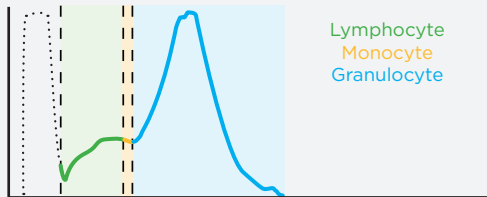
Histograms are graphical representations of the blood cell populations. In a histogram, cells are separated according to their cell type based on their size, with each peak representing a different cell type. Histograms can help verify the differential cell counts, serve as a quality control check, identify uncommon disease processes, and indicate sample integrity.

- The area under the curve is equal to the relative cell count for the specific sample run.
- Histograms will vary from sample to sample, and the peak height of a histogram cannot be compared between different sample runs.



Normal Histograms^{1,2}

White Blood Cells (WBC) Histogram



White Blood Cells. The peaks in the WBC histogram, separated by discriminators, correspond with LYM, MON, and GRA. Debris (lysed RBCs) from the WBC counting step may be seen to the left of the first discriminator.

- **Lymphocyte.** The LYM peak (left) is seen to the right of the first discriminator. In canines, the LYM peak starts on the low-to-mid portion along the Y-axis, as shown, indicating lower populations of this cell type. In felines, the LYM peak starts on the mid-to-high portion of the y-axis due to higher relative number of LYM in cats.
- **Monocyte.** The MON peak (center) is seen to the right of the second discriminator, and is typically shorter due to a smaller population relative to other WBCs.
- **Granulocyte.** The GRA peak (right) is seen to the right of the third discriminator, and is predominantly comprised of neutrophils. It is the tallest and widest peak, indicating it is the most numerous WBC population.

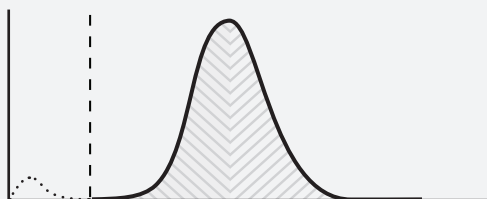
Eosinophil (EOS) Histogram



Eosinophil. The EOS histogram varies and may be symmetrical or asymmetrical, jagged or smooth. Debris (lysed cells) from the EOS counting step may be seen to the left of the discriminator. It is not uncommon for the EOS discriminator to appear on the edge of the EOS peak.

- The eosinophils are counted separately from the other WBC types, and are thus shown in a separate histogram.
- Interpreting EOS by focusing on the numerical HM5 data is recommended.

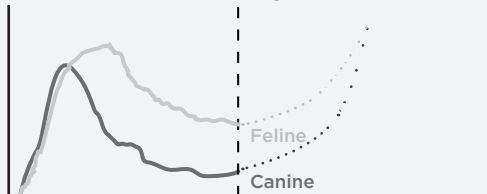Red Blood Cells (RBC) Histogram



Red Blood Cells. The RBC histogram in normal dogs and cats should present as an almost symmetrical, bell-shaped curve. The PLT peak can be seen to the left of the discriminator.

- The width of the curve relates to the red cell distribution width (RDW).
- An increased RDW would show on the RBC histogram as a wider peak, and mean that some of the RBCs are either larger and/or smaller than normal.
- RDW measures anisocytosis, or RBC size variation.

Platelet (PLT) Histogram

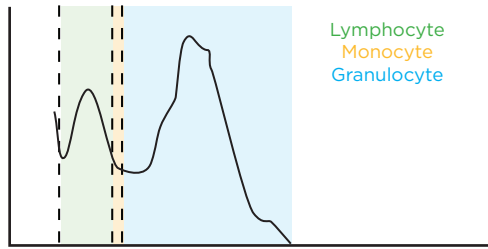


Platelet. The PLT histogram begins with a sharp increase to a peak and tapers downward as cell size increases. This indicates that the majority of platelets are smaller in size, with fewer large sized platelets. The RBC peak can be seen starting to the right of the discriminator.

- In felines, the histogram tapers downward more slowly, indicating more cells of a larger size, commonly associated with mild platelet clumping.
- The reported PLT number is the minimum number of free platelets counted by the analyzer.
- PLT histogram should be evaluated whenever the PLT count is low and/or lymphocytes are elevated. A blood smear to confirm a low platelet count is also recommended.

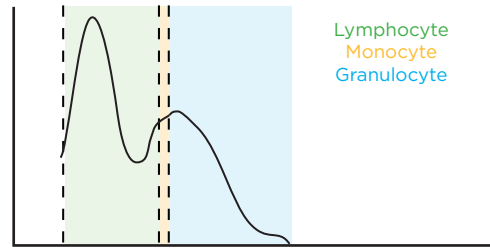
Histogram Case Studies

Normal WBC Histogram (Feline)³



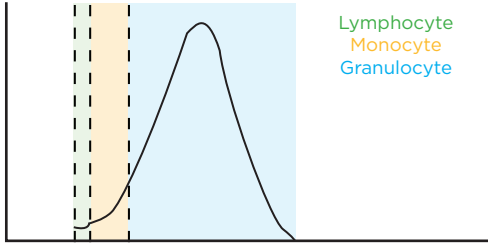
- Distinct LYM peak and GRA peaks.
- LYM begins in upper-middle of Y-axis, higher than in canines which begin lower on the Y-axis.

Lymphocytosis WBC Histogram (Canine)³



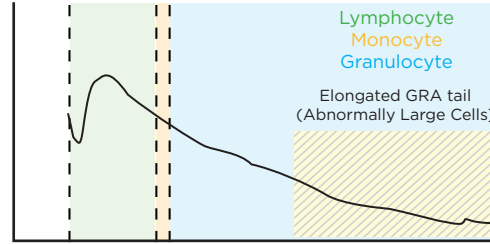
- Tall LYM peak indicates large numbers of this cell type.
- Narrowed GRA peak, with “flattened” area under the curve, indicates a relative neutropenia.

Stress Leukogram WBC Histogram (Canine)³



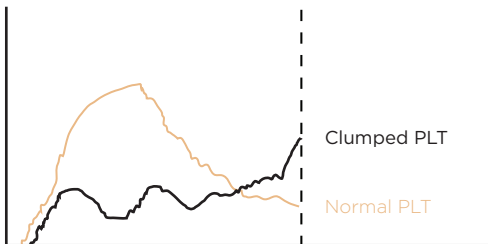
- Low LYM and/or MON peak.
- A peak of primarily GRA is seen, indicating a relative lymphopenia and neutrophilia.
- Feline stress leukogram WBC histogram has similar appearance.

Leukemia WBC Histogram (Canine)⁴



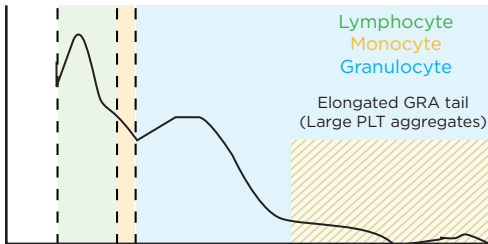
- LYM, GRA peaks are often indistinct as cells may vary in size and are not homogenous.
- Elongated GRA tail indicates presence of larger cells.

Clumped Platelets PLT Histogram (Feline)³



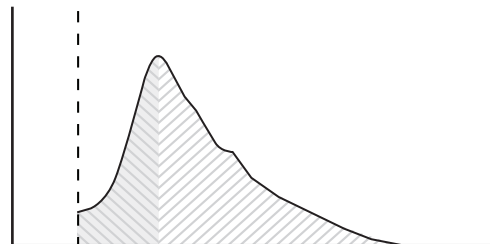
- PLT histogram peak slopes up toward the right, indicating the presence of larger PLT clumps and fewer individual PLT.
- Reported PLT count may be falsely decreased.
- A blood smear to confirm a severely low platelet count is recommended.

WBC Histogram (Feline)¹



- In severe cases of PLT clumping, WBC histogram may show clumped platelets falsely counted as LYM (smaller aggregates) and/or GRA (larger aggregates).
- Elongated GRA tail represents large PLT aggregates.
- Reported WBC count may be falsely increased with severe PLT clumping.

Regenerative Anemia RBC Histogram (Feline)⁵



- RBC histogram is asymmetrical and weighted toward the right, indicating the presence of larger sized RBC (reticulocytes and/or immature RBCs).

RBC Results (Feline)

RBC:	-	3.78	$10^{12}/l$	5		10
HGB:	-	5.9	g/dL	8		15
HCT:	-	19.17	%	24		45
MCV:		51	fl	39		55
MCH:		15.7	pg	12.5		17.5
MCHC:		30.8	g/dL	30		36
RDWc:	+	24.0	%			

- RDWc measures anisocytosis, or RBC size variation.
- RDWc and histogram indicate a regenerative response despite normocytic, normochromic anemia.
- RDWc will be elevated in moderate to severe cases (>20% cell size variation) due to large RBC sizes, as indicated by the histogram asymmetry.